

Submandibular Duct Fistula Caused by a Large Sialolith: Incidental Finding in a Barium Swallow Study

Kathleen Ann Stanford, BS, R.T.(R)

Background This case report details an incidental finding of a submandibular duct fistula to a patient's posterior mouth floor found on a barium swallow examination that was performed to rule out gastrological causes of substernal chest pain. The radiologist was unable to determine the cause of the filling defect at the time of the study. The patient's history revealed that a large calculus of unknown size had been passed spontaneously through the floor of the mouth, rupturing the proximal gland duct and creating the fistula.

Discussion Sialolithiasis is the formation of calculi in the salivary gland and is the most common disease of the salivary glands, with the submandibular glands affected more often than others. The condition is more common in men than in women and most often affects individuals aged between 30 and 60 years.

Conclusion In general, the etiology of sialolithiasis is unknown. However, examining comorbidities and possible risk factors, such as tobacco use, and how they alter the saliva and the function of the salivary glands might lead to a better understanding of their cause.

The barium swallow is a fluoroscopic examination that demonstrates the anatomy of the oral cavity, as well as the pharynx, and assesses a patient's ability to swallow.¹ The study can reveal various abnormalities, including congenital malformations, diverticula, fistulas, inflammatory disease, cysts, foreign bodies, and benign or malignant lesions.² Barium swallows are not intended to study the salivary glands; rather, sialography is used to assess the function of or abnormalities in the salivary glands.

Sialolithiasis is the formation of calculi in a salivary gland and is the most common disease of the salivary glands.^{3,4} Submandibular glands are affected by calculi more often than are parotid glands,³⁻⁵ followed by sublingual glands, and then by minor glands.³ Compared with other salivary glands, the submandibular gland has higher mucin levels, a larger duct, higher calcium levels, more alkaline saliva, and saliva that moves slower and against gravity, qualities that might contribute to calculi formation.⁶ In addition, intraductal calculi are

more common than are glandular calculi.⁷ Sialolithiasis is more common in men than in women.^{3,7} Although the disease can occur at any age, it is most prevalent in people aged 30 to 60 years.⁴ The common presentation of sialoliths is pain and swelling in the gland from the obstructive nature of the calculus. Symptoms are particularly apparent during meals, when salivary secretion is most active.^{5,8}

Salivary calculi have both organic and inorganic components.^{5,9,10} Phosphate apatite is the mineral most often found in calculi and is present throughout.¹⁰⁻¹³ Whitlockite, a calcium phosphate, is the second most common material found in calculi, but it is found most often in the center of the calculi.¹¹⁻¹³ The exact cause of calculi formation in the salivary glands is unknown.^{3,5,9,10,14} In general, calculi range in size from 1 mm to less than 1 cm.⁴

Salivary fistulas are rare and usually are caused by calculi, direct trauma, or foreign bodies.^{15,16} Congenital salivary fistulas also have been documented.¹⁵

Literature Review

Almasri reported the case of a 70-year-old man who had a neck fistula caused by an intact 2.3 cm × 1.7 cm calculus.³ In an analysis of 3 case studies, Asfar et al noted the case of a 55-year-old man with a calculus measuring 3.8 cm × 2.5 cm that created a fistula reaching from the submandibular gland to the oral cavity.¹⁷ Nemade et al reported on a 46-year-old man with a fistula formed by a 1.6 cm × 1.0 cm calculus.¹⁸ Akin and Esmer also reported a 4.5 cm × 3.0 cm calculus that had entirely eroded through the epithelial layer of the submandibular duct in a 45-year-old man.¹⁹ In a report by Sutay et al, a 22-year-old woman had a 3.7 cm × 0.7 cm “comma shaped” submandibular calculus that caused a fistula in association with sialadenitis.¹⁶

The patient in this case report had a submandibular fistula created by a sialolith. Its discovery was incidental, unlike many other cases. Understanding how a fistula appears under fluoroscopy is of diagnostic value to radiologists and radiologic technologists.

Case Description

A 56-year-old woman presented with severe substernal and epigastric pain. She had a history of chronic back pain (possibly due to ankylosing spondylitis), chronic obstructive pulmonary disease, and visits to the emergency department for shortness of breath. During this complaint of chest pain, she had a stress test and the result was negative.

After a referral to a gastroenterologist, the patient underwent a barium swallow study to evaluate her for gastroesophageal reflux disease, hiatal hernia, or esophageal spasm. The fluoroscopy examination revealed a filling defect. A branching tract extending from the oral cavity had filled with and was retaining barium (see **Figure**). During the examination, the resident radiologist was uncertain what caused this branching appearance. The radiology report vaguely described it as “a contrast-opacified tract in the area of the right submandibular gland.” The barium swallow was considered otherwise unremarkable.

Upon review and referral to the otolaryngology department, the patient discussed her history of sialolithiasis. The patient had not had a recurrence of salivary calculi in 4 or 5 years, but prior to that time she had

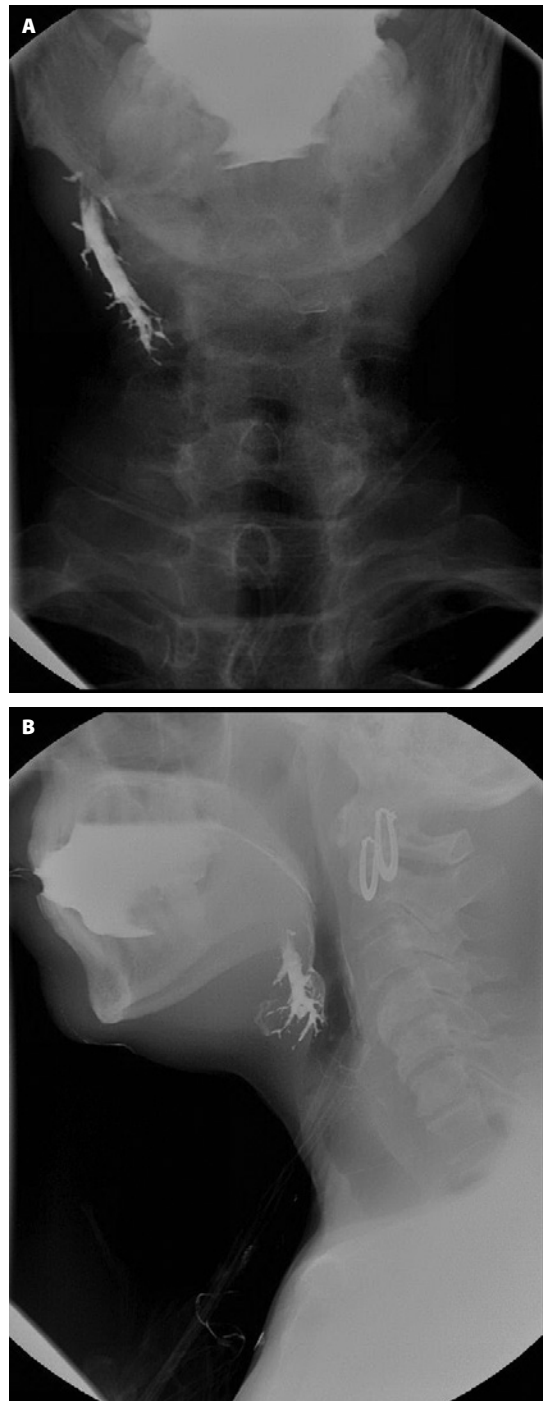


Figure. Anteroposterior (A) and lateral (B) fluoroscopy images showing a branching tract retaining barium in the area of the submandibular gland. Images courtesy of the author.

passed multiple calculi, including a very large one. She reported that despite its large size, she passed it spontaneously. A physical examination by an otolaryngologist revealed a salivary fistula between the right submandibular gland and the posterior floor of her mouth—likely a ruptured proximal salivary gland duct caused by the ejection of the sialolith. Upon manipulation of the right submandibular gland, the physician noted that the posterior floor of the patient's mouth had abundant, thin salivary outflow. Despite the negative stress test result, the physician recommended that the patient seek help from a cardiologist to rule out vasospastic angina as a cause of her chest pain. No treatment was recommended for the fistula.

Discussion

A sialolith is considered to be a giant salivary calculus if it is larger than 1.5 cm.^{20,21} In their literature review of giant sialoliths, Ledesma-Montes et al reported that the patients in all 16 of the case studies they analyzed were men.⁴ Those studies focused on salivary calculi measuring 3.5 cm or more. The patient in this study self-reported her experience with a large salivary calculus, so there is no accurate medical or radiographic record with which to estimate its size; this is a major limitation of the case report. Regardless, a case of large salivary calculus in a woman is an interesting finding when many sialolith case studies have reported the calculi in men. It is an especially rare case considering this patient's calculi created a fistula and because the finding of a fistula occurred incidentally during a radiographic examination. Other cases in the literature review reported that the fistulas were discovered by oral cavity examinations.

McFerran et al studied a patient who also had a right submandibular gland fistula to the oropharynx incidentally found by a barium swallow study.¹⁵ The 41-year-old woman in that study presented with a sensation of a lump in her throat that diminished when she swallowed and increased during periods of stress.¹⁵ A barium swallow study showed that the side branches of the duct were communicating with the oral cavity. The patient had no history of surgery to the area or sialolithiasis, and the origin was found to be congenital in nature.¹⁵

In this case study, the patient's report of her sialolith spontaneously passing through the oral cavity also

should be noted. Of the patients discussed in the literature review, Sutay et al reported on the only one who did not require surgery to remove the calculus; that female patient's calculus was removed transorally.¹⁶

Examining comorbidities might help to understand the etiology of sialolithiasis. Smoking has been shown to decrease salivary antioxidants, such as peroxidase, and reduce phagocytic functions.²² A study by Huoh et al examined the demographic and comorbid conditions of 153 patients with sialolithiasis and reported that 44% of the sample had a history of smoking. Furthermore, both smoking histories and current smoking rates were higher in the sample than in the general population.²³ However, smoking and sialolith size were not correlated.²³ The patient in the study by Almasri had a 30-year history of heavy smoking.³

The patient in this case report also was a heavy smoker for many years, smoking up to one pack a day. She had been advised to stop smoking since receiving her diagnosis of chronic obstructive pulmonary disease following an emergency department visit for dyspnea; she ceased smoking a few months later. The patient was using oxygen at 2 L/min via nasal cannula, 24 hours per day. Laforgia et al found in a study of 400 cases of sialolithiasis that 25% of those sampled had diabetes and 20% had hypertension.⁷ The patient in this case had a history of hypertension but was not diagnosed with diabetes.

Conclusion

Publication of images and case studies of rare findings is significant in improving accurate, timely diagnosis and can help radiologists and radiologic technologists better understand and recognize salivary fistulas in barium swallow examinations. Further study of the etiology of sialolithiasis, including causes of giant sialoliths, is needed. Examining comorbidities and possible risk factors, such as tobacco use, and how they alter the function of the salivary glands and saliva might improve understanding of the cause of salivary calculi.

Kathleen Ann Stanford, BS, R.T.(R), is an alumna of the University of North Carolina at Chapel Hill. She works at WakeMed Imaging Services in Raleigh, North Carolina.

Received July 7, 2014; accepted after revision August 15, 2014.

Reprint requests may be mailed to the American Society of Radiologic Technologists, Communications Department, at 15000 Central Ave SE, Albuquerque, NM 87123-3909, or e-mailed to communications@asrt.org.

© 2015 American Society of Radiologic Technologists

References

- Logemann JA. Role of the modified barium swallow in management of patients with dysphagia. *Otolaryngol Head Neck Surg*. 1997;116(3):335-338.
- Tao TY, Menias CO, Herman TE, McAlister WH, Balfe DM. Easier to swallow: pictorial review of structural findings of the pharynx at barium pharyngography. *Radiographics*. 2013;33(7):e189-e208. doi:10.1148/rg.337125153.
- Almasri M. Management of giant intraglandular submandibular sialolith with neck fistula. *Ann Dent*. 2005;12(1):41-46.
- Ledesma-Montes C, Garcés-Ortiz M, Salcido-García JF, Hernández-Flores F, Hernández-Guerrero JC. Giant sialolith: case report and review of the literature. *J Oral Maxillofac Surg*. 2007;65(1):128-130. doi:10.1016/j.joms.2005.10.053.
- Marchal F, Dulguerov P. Sialolithiasis management: the state of the art. *Arch Otolaryngol Head Neck Surg*. 2003;129(9):951-956.
- Williams MF. Sialolithiasis. *Otolaryngol Clin North Am*. 1999;32(5):819-834.
- Laforgia PD, Favia GF, Chiaravalle N, Lacaita MG, Laforgia A. Clinico-statistical, morphologic and microstructural analysis of 400 cases of sialolithiasis. *Minerva Stomatol*. 1989;38(12):1329-1336.
- Baurmash HD. Submandibular salivary stones: current management modalities. *J Oral Maxillofac Surg*. 2004;62(3):369-378. doi:10.1016/j.joms.2003.05.011.
- Hiraide F, Nomura Y. The fine surface structure and composition of salivary calculi. *Laryngoscope*. 1980;90(1):152-158.
- Grases F, Santiago C, Simonet BM, Costa-Bauzá A. Sialolithiasis: mechanism of calculi formation and etiologic factors. *Clin Chim Acta*. 2003;334(1-2):131-136. doi:10.1016/S0009-8981(03)00227-4.
- Yamamoto H, Sakae T, Takagi M, Otake S. Scanning electron microscopic and x-ray microdiffractometric studies on sialolith-crystals in human submandibular glands. *Acta Pathol Jpn*. 1984;34(1):47-53.
- Burstein LS, Boskey AL, Tannenbaum PJ, Posner AS, Mandel ID. The crystal chemistry of submandibular and parotid salivary gland stones. *J Oral Pathol*. 1979;8(5):284-291.
- Anneroth G, Eneroth CM, Isacsson G. Crystalline structure of salivary calculi. *J Oral Pathol*. 1975;4(5):266-272.
- Ashby R. The chemistry of sialoliths - stones and their homes. In: Norman JED, McGurk M, eds. *Color Atlas and Text of the Salivary Glands: Diseases, Disorders, and Surgery*. London, England: Mosby-Wolfe. 1995:243-251.
- McFerran DJ, Phillips RR. Case report: congenital fistula between the submandibular gland and the oropharynx. *Br J Radiol*. 1993;66(786):561-562.
- Sutay S, Erdag TK, Ikiz AO, Guneri EA. Large submandibular gland calculus with perforation of the floor of the mouth. *Otolaryngol Head Neck Surg*. 2003;128(4):587-588.
- Asfar SK, Steitiyeh MR, Abdul-Amir R. Giant salivary calculi: an orocervical fistula caused by a submandibular gland calculus. *Can J Surg*. 1989;32(4):295-296.
- Nemade SV, Rokade VV, Pathak NA. A giant sialolith with perforation of the floor of mouth. *Otolaryngol Online J*. 2013;3(4):171-184.
- Akin I, Esmer N. A submandibular sialolith of unusual size: a case report. *J Otolaryngol*. 1991;20(2):123-125.
- Bodner L. Giant salivary gland calculi: diagnostic imaging and surgical management. *Oral Surg Oral Med Oral Pathol Oral Radiol Endod*. 2002;94(3):320-323.
- Soares EC, Costa FW, Pessoa RM, Bezerra TP. Giant salivary calculus of the submandibular gland. *Otolaryngol Head Neck Surg*. 2009;140(1):128-129. doi:10.1016/otohns.2008.08.018.
- Nagler RM, Klein I, Zarzhevsky N, Drigues N, Reznick AZ. Characterization of the differentiated antioxidant profile of human saliva. *Free Radic Biol Med*. 2002;32(3):268-277.
- Huoh KC, Eisele DW. Etiologic factors in sialolithiasis. *Otolaryngol Head Neck Surg*. 2011;145(6):935-939. doi:10.1177/0194599811415489.



Have you ever performed a study that revealed incidental findings? Share it with your ASRT Communities at www.asrt.org/myasrt.